

Case Report

Megacystis- microcolon -intestinal hypoperistalsis syndrome(MMIHS)

Dr Abhinav Tiwari , Dr Bijal Shrivastava , Dr Pankaj Dargu

Name of the Institute/college: Dr L.H.Hiranandani Hospital, Mumbai

Corresponding author :Dr Abhinav Tiwari

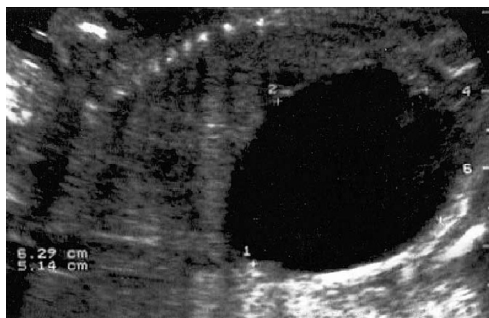
Introduction

Megacystis- microcolon -intestinal hypoperistalsis syndrome(MMIHS) also called as BERDON SYNDROME is a rare congenital disease characterized by massive abdominal distension caused by a largely dilated non-obstructed urinary bladder, microcolon and decreased or absent intestinal peristalsis. It poses a diagnostic and therapeutic challenge to the surgeon. It the most severe form of functional intestinal obstruction in the newborn. Most patients with MMIHS are not able to void spontaneously. Long term prognosis is bad. We report you this rarity with a review of various aspect of disease.

Keywords: Megacystis microcolon intestinal hypoperistalsis syndrome , Functional intestinal obstruction

Case report:

A near term (36 weeks)Female child born through LSCS delivery to Gravida three surrogate mother in view of polyhydramnios. Pre natal USG was suggestive of MMIHS which shows enlarged bladder, polyhydramnios with macrosomia. On examination, baby had large abdomen which was hypotonic and bowel sound was sluggish. Baby passed urine after decompression

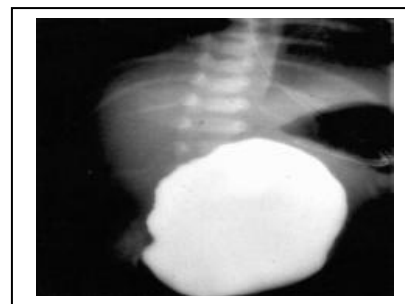


Large fetal bladder seen on a longitudinal view of abdominal ultrasound

A plain X RAY abdomen shows gas filled distension of bowel loops.USG KUB shows severe dilatation of pelvicalyceal system (severe hydronephrosis) with

thinning of renal parenchyma and bladder is grossly dilated. It is causing displacement of abdominal viscera. No other abnormality noted in 2D ECHO and NSG.

Patient was kept NBM and IV fluids were started. As the baby was not passing urine, catheterisation was done. To rule out other anomaly barium enema was done which shows normal passage of barium in retrograde direction upto splenic flexure with luminal caliber is significant narrowing throughout. No stricture and rectum appears to be extremely narrow. Nephrologist opinion was taken and fluid management was done as per the advice.



A contrast enema showing microcolon in an MMIHS patient.

On 5th day of life baby underwent exploratory laparotomy with ileostomy and a vesiculostomy. Megacystis and microcolon were the two most frequent finding at surgery. Malrotation was found, which was corrected. Vesiculostomy was done decompress the urinary tract and to preserve renal function as creatinine values were on the higher before the surgery.

Child tolerated the procedure well, and there was no post operative complication. Child was kept on total parental nutrition and was discharged against medical advice. As parents were from Australia baby was taken there. Bad prognosis was explained to them. Baby was discharged with continuous RT aspirates, IV fluids, suprapubic catheter draining urine.

Discussion

There are more the 200 cases reported till now. The review presented here is done in the aim of drawing positive conclusion on the basis of various facts scattered in the report. Etiology is not understood. No firm report is there to attribute any particular factors. Some authors have mentioned regarding the genetic, neurogenic, myogenic and hormonal origin however the etiology of this syndrome remains unclear.

Dr Puri and coworkers showed, in 1983, vacular degenerative changes in the smooth muscle cells (SMCs) with abundant connective tissue between muscle cells in the bowel and bladder of patients with MMIHS and suggested that a degenerative disease of

smooth muscle cells could be the cause of this syndrome. Several subsequent reports have confirmed evidence of intestinal myopathy in MMIHS. Female are recognized more than the male and autosomal recessive pattern has been recognized.

Reported familial occurrence of the disease in 2 or 3 sibling. Consanguinity is reported.

Prenatal diagnosis of MMIHS is mostly based on fetal ultrasound, revealing enlarged urinary bladder and hydronephrosis. Recent reports have proposed prenatal magnetic resonance imaging (MRI) in combination with analysis of enzymatic changes to contribute to prenatal diagnosis of MMIHS. The enlarged bladder can be observed from the second trimester and polyhydramnios from the third.

There is no curative treatment for MMIHS. Various surgical interventions including gastrostomy, jejunostomy and vesicostomy have been reported and have been generally unsuccessful in most patients. Several multivisceral transplantations have also been reported. In the majority of patients total parenteral nutrition is required. Survival in MMIHS seems to have improved, thanks to more specialized care, innovations in parenteral nutrition, and introduction of multivisceral transplantation. However, prognosis and life expectancy of this generally fatal disease remains poor. Death is mainly caused by sepsis, malnutrition or multiple organ failure.

The longest survival noted was 7 years and required 25 separate central venous catheter insertion.

References:

1. Berdon WE, Baker DH, Blanc WA, et al: Megacystis-microcolon-intestinal-hypoperistalsis syndrome. A new cause of intestinal obstruction in the newborn. Report of radiologic findings in five newborn girls. *Am J Roentgenol* 126:957-964, 1976.

2. Puri P, Lake BD, Gorman F, et al: Megacystis-microcolon-intestinal hypoperistalsis syndrome: A visceral myopathy. *J Pediatr Surg* 18:64-69, 1983
3. Yokoyama S, Fujimoto T, Tokuda J, et al: Successful nutrition management of megacystis-microcolon-intestinal hypoperistalsis syndrome: A case report. *Nutrition* 5:423-426, 1989
4. Patel R, Carty H: Megacystis-microcolon-intestinal hypoperistalsis syndrome: A rare case of intestinal obstruction in the newborn. *Br J Radiol* 53:249-252, 1980
5. Srikanth MS, Ford EG, Isaacs H, et al: Megacystis microcolon intestinal hypoperistalsis syndrome: Late sequelae and possible pathogenesis. *J Pediatr Surg* 28:957-959, 1993
6. Rolle U, O'Briain S, Pearl RH, et al: Megacystis-microcolon-intestinal hypoperistalsis syndrome: Evidence of intestinal myopathy. *Pediatric Surg Int* 18:2-5, 2002
7. Jimenez Gil de Muro ST, Moros Pena M, Gimeno Pita P, et al: Megacystis-microcolon-intestinal hypoperistalsis syndrome: A case of prolonged survival. *An Pediatr* 60:369-372, 2004
8. Dewan PA, Brown N, Murthy DP, et al: Hydrometrocolpos and segmental colonic dilatation in a girl with megacystis-microcolon-intestinal hypoperistalsis syndrome. *J Paediatr Child Health* 31:479-482, 1995
9. Kobayashi H, O'Briain S, Puri P: New observation on the pathogenesis of Megacystis microcolon intestinal hypoperistalsis syndrome. Presentation at the Meeting of the American Pediatric Surgical Association, Boca Raton, FL, 1995
10. Bloom TL, Kolon TF: Severe megacystis and bilateral hydronephrosis in a female fetus. *Urology* 60:697, 2002
11. Kim KC: Megacystis-microcolon-intestinal hypoperistalsis syndrome. *Ryoikibetsu Shokogun Shirizu* 34:159, 2001
12. Witters I, Theyskens C, van Hoestenbergh R, et al: Prenatal diagnosis of non-obstructive megacystis as part of the megacystis-microcolon-intestinal hypoperistalsis syndrome with favourable
13. Piotrowska AP, Role U, Chertin B, et al: Alterations in smooth muscle contractile and cytoskeleton proteins and interstitial cells of Cajal in megacystis microcolon intestinal hypoperistalsis syndrome. *J Pediatr Surg* 38:749-755, 2003
14. Xu W, Gelber S, Orr-Urtreger A, et al: Megacystis, mydriasis and ion channel defect in mice lacking the alpha3 neuronal nicotinic acetylcholine receptor. *Proc Natl Acad Sci USA* 96:5746-5751, 1999